


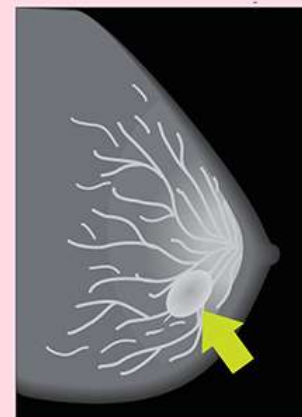
MAMOGRAFIJA



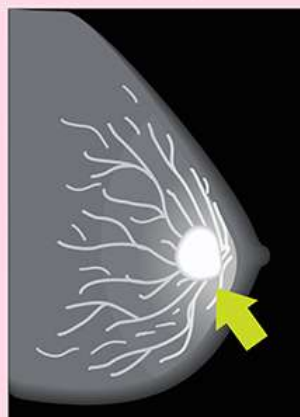
Normalni mamogram



Benigna cista (nije karcinom)



Karcinom



Kalcijum

